Imaging and In Vivo Quantitation of β-Amyloid: An Exemplary Biomarker for Alzheimer's Disease?

Lisa Nichols, Victor W. Pike, Lisheng Cai, and Robert B. Innis

Alzheimer's disease (AD) is characterized pathologically by the presence of β-amyloid plaques in the brain. A substantial body of research indicates that the presence of increased β-amyloid peptide (Aβ) is neurotoxic and may initiate the further pathology observed in AD, including neurofibrillary tangles, synaptic loss and dysfunction, and neurodegeneration. The use of brain imaging in patients with or at risk for AD has increased our understanding of the pathophysiology of the disease and may potentially aid in diagnosis. The development of new therapeutics that reduce Aβ in the brain has also indicated a potential use for amyloid imaging in monitoring response to treatment. This review explores the utility of amyloid as a biomarker and the use of positron emission tomography and magnetic resonance imaging in the diagnosis and treatment of AD.

Key Words: Alzheimer's disease, imaging, amyloid, biomarker, PET, MRI

Alzheimer's disease (AD) is characterized by progressive deterioration of memory and other cognitive function, which may be accompanied by behavioral symptoms including agitation, anxiety, depression, or psychosis. Alzheimer's disease currently afflicts approximately 4.5 million Americans (Hebert et al 2003), and the incidence will substantially increase as a larger proportion of US citizens reaches the age of susceptibility. One goal of current drug development is the reduction or elimination of β-amyloid plaques, a hallmark of this disease and the marker by which diagnosis is confirmed posthumously. Positron emission tomography (PET) radioligands that bind selectively to amyloid could allow for the assessment of both the severity of disease in vivo and the effectiveness of new drugs that aim to reduce amyloid plaques. This article reviews the potential utility of amyloid as a biomarker of AD and the often overlooked limitations of amyloid imaging in diagnosis and monitoring of treatment.

The Argument for Amyloid as an Etiological Factor in AD

While the cause of AD is unknown, the discovery of amyloid plaques and neurofibrillary tangles (NFTs) by Aloise Alzheimer in 1907 generated several hypotheses and guided the development of disease models. The amyloid cascade hypothesis posits that environmental or genetic factors enhance secretion and/or reduce clearance of the β-amyloid peptide (Aβ), resulting in the formation of amyloid plaques (Hardy and Selkoe 2002; Hardy and Higgins 1992). The Aβ peptide is a product of the proteolytic cleavage of the amyloid precursor protein (APP), which can be processed via two pathways (Figure 1) (Shoghi-Jadid et al 2005). In the first, APP cleavage by α-secretase produces a soluble *N*-terminal fragment (sAPPα) and a membrane-bound *C*-terminal fragment (C83). In the second pathway, β- and γ-secretase sequentially cleave APP to produce $A\beta_{40}$ and $A\beta_{42}$. The enzyme β-secretase (BACE1) cleaves APP at the *N*-terminus of the Aβ sequence and produces a 99-amino acid *C*-terminal fragment (C99), which is further processed by γ-secretase (Nunan and Small 2002; Puglielli et al 2003). The cleavage site of γ-secretase, a complex consisting of presenilin, nicastrin, APH1, and PEN-2, determines whether $A\beta_{40}$ or $A\beta_{42}$ is produced (Edbauer et al 2003). Accumulation of Aβ, through the transformation of this peptide into oligomers, fibrils, and later plaques, may lead to changes in the brain including an imbalance of kinase and phosphatase activity, resulting in the hyperphosphorylation of tau protein and subsequent development of NFTs, as well as neurotransmitter deficits and neurodegeneration (Selkoe 2004).

A growing body of evidence indicates that soluble Aβ or Aβ oligomers (also referred to as Aβ-derived diffusable ligands [ADDL]) and not insoluble plaques are the precursor to the pathophysiology in AD (Klein et al 2001). McLean et al (1999) found that soluble Aβ, but not Aβ plaques, was significantly correlated with the density of tau-reactive neuritic plaques and NFTs in the cortex and putamen of postmortem AD brain. Soluble $A\beta_{40}$, but not Aβ plaques or NFTs, was also found to be significantly correlated with synaptic loss in postmortem brain specimens from patients with AD (Lue et al 1999). In accordance with these results, Mucke et al (2000) found that transgenic mice carrying a wild-type version of the human gene for APP demonstrated a decrease in presynaptic terminals with age in the absence of amyloid plaques, which correlated with levels of soluble Aβ (Klein et al 2001).

Although the mechanism by which Aβ accumulation stimulates the development of NFTs has only been hypothesized, several studies have linked the two phenomena. JNPL3 mice, which overexpress a mutated version of the human gene for tau and develop NFTs, demonstrate a fivefold increase in NFTs after injection of $A\beta_{42}$ fibrils in brain (Gotz et al 2004) and a sevenfold increase when crossed with mice containing a mutated version of human APP (Lewis et al 2001).

Oddo et al (2003) recently demonstrated a direct relationship between Aβ and tau pathology. They found that passive immunization of transgenic mice, which develop both amyloid plaques and NFTs, not only markedly reduced intracellular and extracellular Aβ but also cleared tau protein from the somatodendritic compartment of neurons and prevented further tau pathology. In contrast, postmortem examination of a woman with AD who had received $A\beta_{42}$ immunizations (AN-1792) found a significant reduction in Aβ plaques and associated dystrophic neurites in neocortical areas but no change in NFTs, neuropil threads, or cerebrovascular amyloid angiopathy (Nicoll et al 2003). These findings suggest that if Aβ immunization proves successful in humans, early detection

From the Molecular Imaging Branch, National Institutes of Health, Bethesda, Maryland.

Address reprint requests to Robert B. Innis, M.D., Ph.D., Molecular Imaging Branch, National Institute of Mental Health, 1 Center Drive MSC-0135, Building 1, Room B3-10, Bethesda, MD 20892-0135; E-mail: robert.innis@nih.gov.

Received June 20, 2005; revised November 1, 2005; accepted November 17, 2005.

0006-3223/06/$32.00
doi:10.1016/j.biopsych.2005.12.004

© 2006 Society of Biological Psychiatry

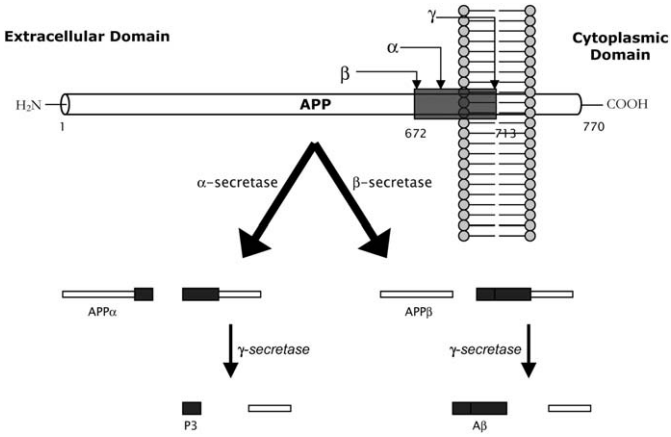

Figure 1. Proteolytic cleavage of APP by α-, β-, and γ-secretases. APP undergoes proteolytic cleavage via two distinct pathways. In the nonamyloidogenic pathway, APP is cleaved by α-secretase resulting in a soluble N-terminal fragment (sAPPα) and a membrane bound C-terminal fragment that is further cleaved by γ-secretase to produce P3. In the second pathway, APP cleavage by β-secretase produces a soluble N-terminal fragment (sAPPβ) and a C-terminal fragment that is further cleaved by γ-secretase to produce $A\beta_{40-43}$. Reprinted with permission from K. Shoghi-Jadid and Elsevier Publishers (Shoghi-Jadid et al 2005). APP, amyloid precursor protein; Aβ, β-amyloid peptide.

and treatment would present the greatest benefit to patients by acting early in the cascade of amyloid-induced pathology.

Significant controversy exists about the correlation, or lack thereof, of amyloid plaques and cognitive decline in patients with AD. Several studies have demonstrated that amyloid plaque deposition is not well correlated with cognitive dysfunction in mild cognitive impairment (MCI) or AD, while other studies have reported significant correlations (Cummings and Cotman 1995; Guillozet et al 2003; Wilcock and Esiri 1982). Studies of total Aβ levels (which account for both the soluble and insoluble forms) have demonstrated significant correlations between $A\beta_{40-42}$ levels and severity of cognitive dysfunction (Naslund et al 2000), as have studies of NFTs and cognitive dysfunction (Guillozet et al 2003; Wilcock and Esiri 1982). Though some correlation appears to exist between plaques and cognitive dysfunction, soluble Aβ or total Aβ levels may have a stronger correlation than plaques alone and NFTs also appear to be strongly correlated with cognitive dysfunction.

While roughly 90% of AD cases are considered sporadic, several genetic mutations for early-onset familial AD (FAD) have been identified. Mutations have been identified in three genes for FAD, including the amyloid precursor protein, presenilin 1, and presenilin 2 genes. These mutations result in increased $A\beta_{42}$ production, strongly implicating the Aβ peptide in the pathogenesis of the disease (Hardy and Higgins 1992; Mudher and Lovestone 2002; Sommer 2002).

The only currently identified genetic risk factor for late-onset AD (which constitutes ~90% to 95% of all AD cases) is the ε4 allele of apolipoprotein E (ApoE). Apolipoprotein E is part of a class of proteins that removes excess cholesterol from the blood. The risk for developing AD has been shown to increase with the number of ε4 alleles; those homozygous for the ε4 allele may have a roughly 14.9% risk of developing AD (Beffert et al 1998; Farrer et al 1997). Apolipoprotein E has also been found to correlate with decreased age of onset and increased number of plaques (Corder et al 1993; Gomez-Isla et al 1996). Mann et al (1997) have demonstrated increased $A\beta_{40}$ and increased density and area of amyloid plaques containing $A\beta_{40}$ in postmortem brain of AD patients with one or two copies of the ApoE ε4 allele. In another postmortem study, Ghebremedhin et al (1998) observed a significantly greater frequency of NFTs in the transentorhinal region (stage 1 of AD-related changes) in brains of individuals (average age 38) heterozygous for the ε4 allele than those who were negative for this risk allele.

Increasing pathological evidence suggests that amyloid deposition begins early in life. A study by Braak and Braak (1997) of 2661 postmortem human brains investigated plaque and tangle pathology in individuals ranging in age from 25 to 95. They demonstrated the presence of early-stage amyloid deposits in some younger adults with increasing prevalence and advanced stages of amyloid deposition with increasing age. Neurofibrillary tangles and neuropil threads were also present in younger adults and increased until roughly the age range of 60 to 70 years of age before declining, while the prevalence of advanced stages of pathology increased with advanced age.

Drug Development: Focus on Mechanisms Targeted for Amyloid

The current treatments available for AD are symptomatic and only partially effective, e.g., cholinesterase inhibitors and the partial *N*-methyl-D-aspartate (NMDA) antagonist, memantine. In contrast, drugs that reduce amyloid burden in brain would treat and potentially prevent the associated neuropathology. The β-secretases and γ-secretases are promising drug targets for AD. The cleavage of APP by β-secretase and γ-secretase produces the $A\beta_{40}$ and $A\beta_{42}$ peptides; drugs which inhibit β-secretase and γ-secretase should significantly reduce production of these peptides.

Immunization against $A\beta_{42}$ has also been studied extensively for treatment of AD in both animal models and patients. Active $A\beta_{42}$ immunization was shown to protect young mice overexpressing mutant human APP (PDAPP mice) from plaque formation and to clear plaques in older animals (Schenk et al 1999). The Aβ immunization has also been shown to improve cognitive performance in APP/PS1 transgenic mice (Gotz et al 2004). In TgCRND8 mice, Aβ immunization reduced plaques by ~50% and also reduced cognitive dysfunction (Janus et al 2000). Interestingly, tau immunization of transgenic mice, which develop both Aβ plaques and NFTs, did not affect either tau or Aβ pathology (Oddo et al 2003).

Clinical studies of active $A\beta_{42}$ immunization have been conducted in patients with AD. A phase IIa trial was discontinued when 6% of the patients developed meningoencephalitis (Orgogozo et al 2003). Data collected from one center showed that 20 of the 30 AD patients who had received immunizations performed significantly better on the Mini-Mental Status Examination and the Disability Assessment for Dementia rating scale than control patients (Hock et al 2003). An interesting paradox is that decreased brain volume and increased ventricular volume were observed in these patients when compared with those who had received placebo (Fox et al 2005). Clinical studies of passive $A\beta_{42}$ immunization are reportedly underway (Selkoe 2004).

The findings of several epidemiological studies suggest nonsteroidal anti-inflammatory drugs (NSAIDs) may reduce the risk of developing AD or delay disease onset (Szekely et al 2004). One study found that cumulative use of NSAIDs for 24 months or greater reduced the risk of developing AD (McGeer et al 1996). Clinical studies of the NSAID naproxen and the cyclo-oxygenase-2 inhibitor, rofecoxib (Vioxx), indicated that these drugs did

not slow the progression of AD (Aisen et al 2003; Reines et al 2004). Furthermore, Weggen et al (2001) found that ibuprofen, indomethacin, and sulindac sulphide, all NSAIDs, decreased production of $A\beta_{42}$ up to 80% in cultured cells regardless of their effects on cyclo-oxygenase activity. Zhou et al (2003) demonstrated that these NSAIDs decreased $A\beta_{42}$ levels through inhibition of Rho, a small G-protein.

Elevated cholesterol levels have been shown to increase Aβ in cellular and animal models (Gotz et al 2004). High-fat/high-cholesterol diets in APP/PS1 transgenic mice increased Aβ levels and deposition of amyloid plaques in brain (Puglielli et al 2003). It has been proposed that drugs such as statins, which inhibit the synthesis of cholesterol, may reduce Aβ levels and protect against AD. Many other treatment strategies have been explored, including agents that disrupt the β-sheet structure of amyloid, copper and zinc chelators, and enzymes such as neprilysin and insulin-degrading enzyme, which have been shown to reduce Aβ deposits (Farris et al 2003) (for a more in-depth review, see Dominguez and De Strooper 2002).

Imaging with PET: Radiopharmaceuticals for Amyloid

Radioligands that bind amyloid plaques are derivatives of histological staining agents that have been used for decades to label amyloid. These agents, like Congo Red and Chrysamine G, have ready access to amyloid plaques in brain sections but would be ineffective as in vivo imaging radioligands. Their high polarity and negative charge prevent them from crossing the blood-brain barrier (BBB) to any significant degree (for an in-depth review of amyloid ligand development, see Mathis et al 2004) and similar complications were encountered with analogs of these compounds. A second complication (or perhaps opportunity) has become apparent: the three-dimensional structure of amyloid aggregates provides multiple binding sites.

At least three classes of binding sites on amyloid plaques have been proposed, including those for Congo Red (a styrylbenzene), thioflavin-T (a benzothiazole), and 2-(1-[6-[(2-[(18)F]-fluoroethyl)(methyl)amino]-2-napthyl]ethylidene)malono nitrile (FDDNP) (an aminonapthalene). In fact, Lockhart et al (2005) recently published data suggesting that the thioflavin-T class itself is composed of three binding sites, termed BS1, BS2, and BS3, for which one binding site is reported to be present per 35, 4, and 300 AB_{40} monomers, respectively. However, controversy exists as to potential overlap and even subtypes of three classes of binding sites (Lockhart et al 2005; Ye et al 2005).

The four promising chemical backbones for amyloid radioligands include aminonapthalenes, benzothiazoles, stilbenes, and imidazopyridines, from which three compounds have been developed and utilized to image amyloid in patients with AD, namely [^{18}F]FDDNP, [^{11}C]PIB, and [^{11}C]SB-13, respectively.

Investigators from the University of California, Los Angeles (UCLA) reported the first in vivo imaging of amyloid plaques in humans using the aminonaphthalene, [^{18}F]FDDNP, in patients with AD and healthy human subjects (Agdeppa et al 2001; Shoghi-Jadid et al 2002). The results demonstrated a significantly greater "relative retention time" in AD subjects over control subjects in the hippocampus, amygdala, and enthorhinal cortex, areas with high concentrations of plaques and tangles. It should be noted that relative retention time has not been validated as an accurate measure of the target.

Nevertheless, greater retention was correlated with poorer performance on cognitive tests, areas of atrophy observed with magnetic resonance imaging (MRI), and low glucose metabolism measured with positron emission tomography with ^{18}fluorodeoxyglucose (FDG-PET). The affinity of FDDNP for synthetic β-amyloid fibrils measured with fluorescence titration assays has been reported to be high, with K_D values of .1 nm and 1.9 nm for two proposed binding sites on amyloid fibrils. Recent studies, however, have indicated that the affinity of this compound for amyloid fibrils may be much lower than previously reported (Ye et al 2005). Limitations of this compound include high nonspecific binding (with a relatively low target-to-background ratio), low brain uptake, and lack of validated kinetic methods for quantitation (Agdeppa et al 2001; Shoghi-Jadid et al 2002). In addition, FDDNP is not specific to amyloid but appears also to bind to neurofibrillary tangles (tau protein) in postmortem AD brain. Finally, FDDNP has been demonstrated to compete for the same binding site on amyloid fibrils as the NSAIDs naproxen and ibuprofen, which may significantly reduce or eliminate the signal from this ligand in individuals taking these medications (Agdeppa et al 2003).

Small et al (2004) recently reported a PET imaging study of [^{18}F]FDDNP in subjects with AD, mild cognitive impairment (which may progress to AD), and no cognitive dysfunction. They reported significantly higher binding in subjects with AD than those with MCI or control subjects and higher binding in MCI patients than in control subjects, indicating the potential use of this compound in the early diagnosis of AD.

Klunk et al (2004a) imaged amyloid in subjects with mild AD and healthy control subjects using the thioflavin-T derivative [^{11}C]PIB (Pittsburgh Compound B, Figure 2). They reported a significant retention of PIB in AD patients, particularly in frontal and temporoparietal areas, compared with healthy control subjects with a ratio between groups of ~2:1 (Klunk et al 2004a). The affinity of PIB for amyloid in AD brain homogenate and synthetic $A\beta_{40}$ is reported to be high, with binding dissociation constants (K_D) of 1 and 5 nm, respectively (Mathis et al 2003). Pittsburgh Compound B has also been demonstrated to bind to amyloid plaques and cerebrovascular amyloid in postmortem AD brain. However, nonspecific binding to white matter has also been reported both in vitro and in vivo and this ligand has been unsuccessful in attempts to label amyloid plaques in transgenic mouse models of AD using PET (Klunk et al 2004a; Mathis et al 2003).

A PET imaging study of [^{11}C]PIB in age-matched subjects with AD, MCI, or with no cognitive dysfunction has been conducted (Klunk et al 2004b). A 2:1 difference in PIB binding was observed between AD patients and control subjects in the frontal, temporal, parietal, and posterior cingulate cortices, while subjects with MCI resembled either control subjects or subjects with AD (Klunk et al 2004b). The MCI patients in this study will require future evaluation to establish the predictive power of [^{11}C]PIB with PET, and the presence of amyloid generally, in the early diagnosis of AD (Klunk et al 2004b).

Verhoeff et al (2004) imaged β-amyloid using the stilbene derivative [^{11}C]SB-13 in subjects with mild to moderate AD and healthy control subjects in a comparison study with [^{11}C]PIB. They found that [^{11}C]SB-13 had similar properties in vivo to [^{11}C]PIB, with greatest retention observed in the frontal and temporoparietal cortices and the striatum of subjects with AD but not control subjects. It should be noted that the sample size in this study was relatively small (n = 11) (Verhoeff et al 2004). In vitro autoradiography indicated specific binding of [^{3}H]SB-13 to amyloid plaques in postmortem AD brain and demonstrated a binding dissociation constant (K_D) of 2.4 nm in AD brain homogenate (Kung et al 2004).

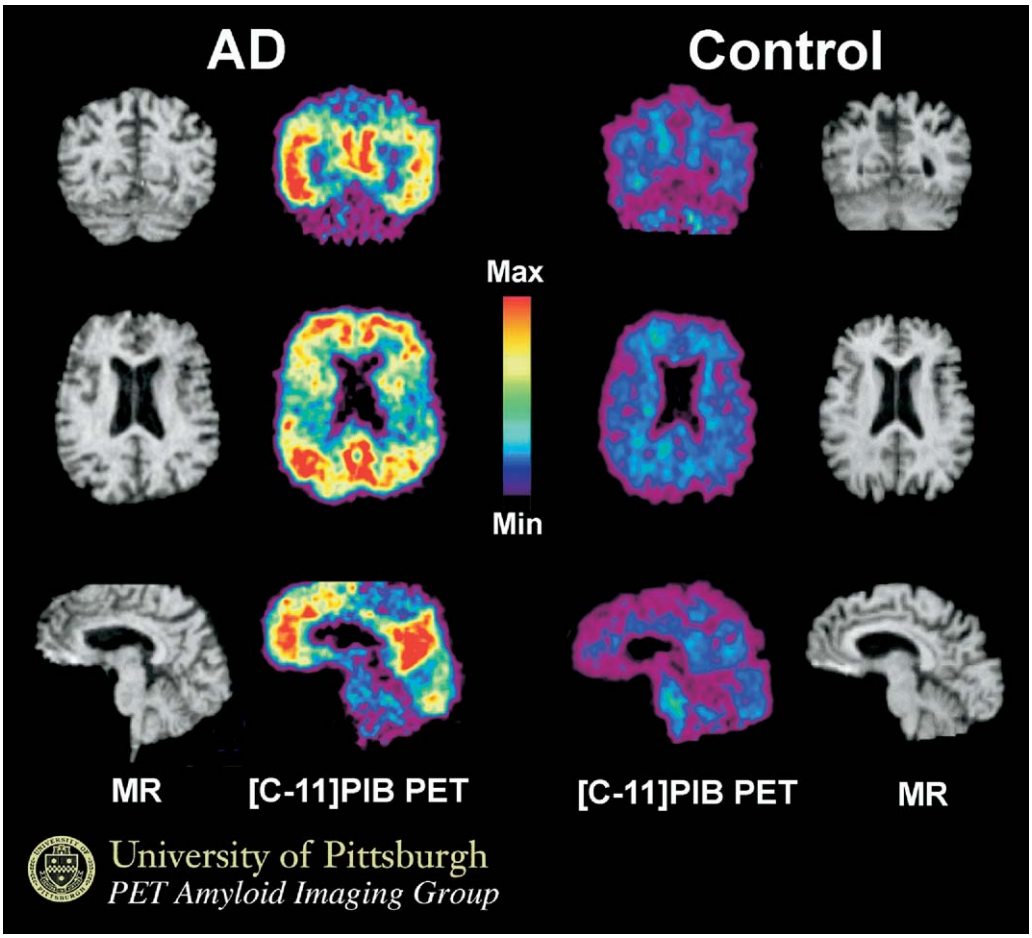

Figure 2. PET images of [^{11}C]PIB in a patient with AD and a healthy subject. A significant retention of PIB is observed in frontal and temporoparietal areas in patients with AD when compared with control subjects. Printed with permission from Chet Mathis. PET, positron emission tomography; PIB, Pittsburgh Compound B; AD, Alzheimer's disease.

These findings suggest that PET radiotracers for amyloid may allow for the early detection of amyloid plaques and diagnosis of the disease, as well as provide a means with which to determine the efficacy of new drugs in development that reduce amyloid levels in brain. This would utilize amyloid as both a biomarker of AD, and a surrogate outcome measure of the efficacy of new therapeutics.

Is Amyloid Imaging a Useful Biomarker or Even Surrogate End Point?

A biomarker is an objectively measured characteristic that reflects either a physiological or pathophysiological process in the human body. For example, plasma cholesterol levels are a biomarker for both normal and pathological processing of this steroid in the body. A biomarker can be used for diagnosis and to study pathophysiology. In contrast, a surrogate end point is a subset of biomarkers that can substitute for the ultimate clinical end point. For example, plasma cholesterol is generally accepted as a surrogate end point in the evaluation of statin medications for the ultimate clinical end point of decreased rate of heart attacks and overall mortality for cardiovascular disease. That is, if a new statin is shown to reduce plasma cholesterol levels, then it can be reasonably assumed to have efficacy in reducing future cardiovascular disease. Imaging of amyloid has frequently been touted as both a useful biomarker (for diagnosis and studies of pathophysiology), as well as a surrogate end point to evaluate medications that reduce the levels of amyloid in the brain. This section will critically evaluate these claims. In brief, the authors think that amyloid is clearly a useful biomarker for pathophysiology, but it may not be adequate for diagnosis and is surely not a validated surrogate end point.

With regard to studies of pathophysiology, amyloid imaging is likely to be a valuable research tool to examine key components of the "amyloid cascade hypothesis" in living human subjects over time. For example, do all patients with AD have significant amyloid in brain? Does clinical progression and physiological sequelae within an individual correlate with the accumulation of amyloid in specific brain regions?

The utility of amyloid imaging for diagnosis or as a surrogate end point is far more questionable than its use to explore pathophysiology. The more extensive imaging studies of the dopamine system in another neurodegenerative disorder, Parkinson's disease (PD), provide a valuable historical comparison (Ravina et al 2005). Many of the symptoms of this idiopathic movement disorder are caused by the degeneration of dopamine neurons in the midbrain, as well as their terminals in the striatum. Similar to amyloid in AD, the imaging of several components of the dopamine system (including dopamine metabolism and the dopamine transporter) were thought to be surely useful to study pathophysiology, to diagnose patients, and to assess the efficacy

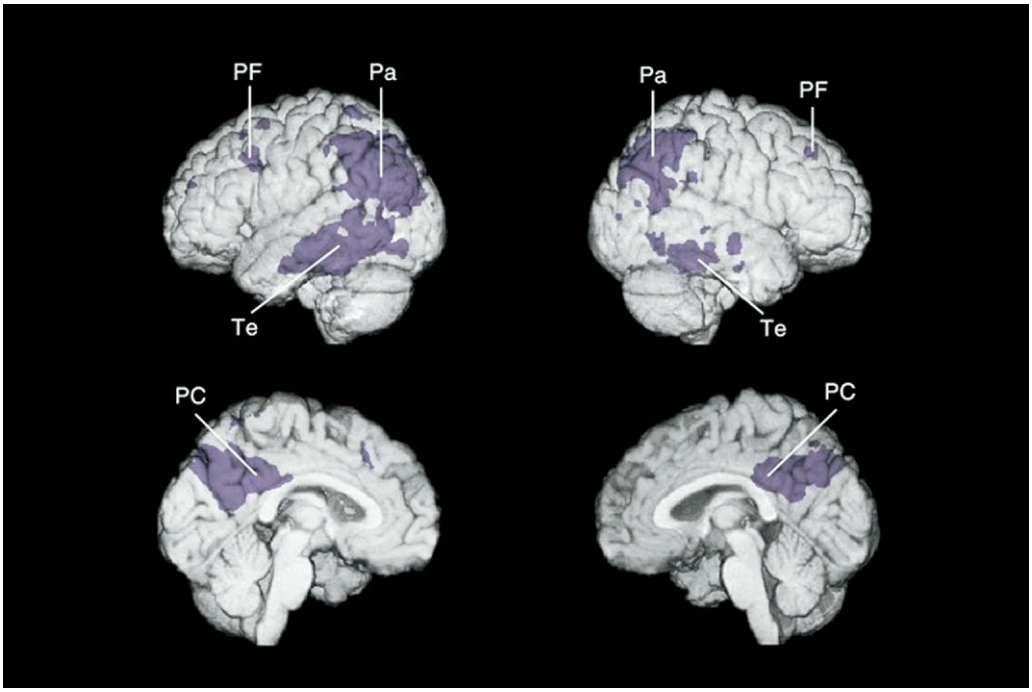

Figure 3. A comparison of positron emission tomography images of cerebral glucose metabolism in patients with probable Alzheimer's disease (AD) and normal controls. The group with probable AD demonstrated significantly reduced rates of glucose metabolism (indicated in purple) bilaterally in the prefrontal (PF), parietal (Pa), temporal (Te), and posterior cingulate (PC) regions when compared with the control group. Reprinted from Reiman et al (1996) with permission from the Massachusetts Medical Society © 1996. All rights reserved.

of putative neuroprotective agents. In fact, such dopamine imaging studies were useful to study pathophysiology, including progression of disease and the evaluation of early stage 1 patients. However, as more studies were completed, it became clear that such dopamine imaging studies largely could not distinguish idiopathic PD from other Parkinsonism, and the false-positive and false-negative rate of imaging for diagnosis is still not clear. Of greater concern, the use of dopamine imaging as a surrogate end point has been severely questioned because of several large studies in which the imaging measurements were discordant from the clinical evaluations. In fact, the National Institute of Neurological Disorders and Stroke (NINDS) sponsored consensus panel on dopamine imaging in PD concluded: "Current evidence does not support the use of imaging as a diagnostic test in clinical practice or as a surrogate end point in clinical trials" (Ravina et al 2005).

This sobering history of dopamine imaging in PD may well be replicated with amyloid imaging in AD. With regard to diagnosis, no reasonable data have yet been published on sensitivity or specificity of amyloid imaging. In fact, preliminary findings reported in abstract form suggest that a moderate percentage of cognitively intact elderly subjects may have abnormally high [^{11}C]PIB brain uptake (Mintun et al 2004). Furthermore, no data exist to support the use of amyloid imaging as a surrogate end point. As a thought experiment, what would have been the utility of amyloid imaging in the human Aβ immunization trial? As mentioned previously, the trial was discontinued because of the 6% occurrence of meningoencephalitis (Orgogozo et al 2003). At least one (and perhaps more) of the subjects was studied at postmortem and thought to have significantly reduced amyloid staining compared with comparable cases. So, let us assume that immunization was effective to remove amyloid from the brain. If imaging were performed, there would be significant discordance between the positive imaging result (i.e., decreased amyloid) and the poor clinical result (i.e., significant meningoencephalitis). Such discrepancies for surrogate end points have occurred before. One frequently quoted example is the use of the electrocardiogram (EKG) to assess the efficacy of flecainide and encainide as antiarrhythmic agents in patients with recent myocardial infarction (Hilts 2003). The Food and Drug Administration (FDA) approved these agents because they corrected the arrhythmia measured on EKG, which was the surrogate end point in this study. However, after several hundred thousand patients were treated with these agents, an National Heart, Lung, and Blood Institute (NHLBI) sponsored study showed that these agents actually increased mortality from cardiac causes! The drugs were withdrawn for use in patients with recent myocardial infarction, although still safe and effective in other patient populations. The research community was alerted that even an obvious surrogate end point (like EKG) with clear face validity needs extensive validation.

Although this discussion takes a rather negative view of amyloid imaging as a surrogate end point, it should be counterbalanced with actual intended use of the tool. From the perspective of a pharmaceutical company developing antiamyloid therapies, the results of imaging might be viewed as "necessary but not sufficient." If the drug is designed to act by removing amyloid and imaging shows that it does not do so, then it could be discontinued because of a failure to demonstrate the proposed mechanism of action. However, even if the imaging results are positive (i.e., show a reduction of amyloid burden), the drug may not improve cognitive function and could have serious side effects. Thus, if the proposed mechanism is to remove amyloid from brain, then a positive effect with imaging would be necessary but not sufficient to establish a useful therapeutic agent.

We must also consider the possibility that imaging of amyloid could be affected by drug therapy, as with dopamine transporter availability. For example, drugs aimed at disrupting amyloid plaques might simply decrease the number of binding sites and therefore the amount of amyloid detected with PET without actually decreasing the total amount of amyloid.

Fleming and DeMets (1996) make an effective argument for the use of the clinical outcome in phase 3 clinical trials in the absence of a well-established surrogate end point measure, which can predict such an outcome. The utility of amyloid as a surrogate outcome measure can only be determined with extensive long-term studies. The correlation, or lack thereof, of amyloid plaques in AD patients with improved cognition and clinical outcome is yet to be determined.

Alternative Imaging Methods: FDG-PET and MRI

The utility of amyloid imaging in AD should also be assessed relative to currently available neuroimaging methods: PET measurement of regional cerebral glucose metabolism and structural MRI. Positron emission tomography with ^{18}fluorodeoxyglucose has been utilized for a number of years to assess glucose metabolic rates in AD patients and has been demonstrated to significantly enhance clinical diagnosis. Positron emission tomography studies of cerebral blood flow, glucose metabolism, and oxygen use have consistently identified parietotemporal hypometabolism in AD patients (Figure 3) and these findings have been correlated with cognitive decline and localization of neurofibrillary tangles (Silverman 2004). These findings can further discriminate AD from vascular or frontotemporal dementia (i.e., Pick's disease) (Silverman 2004). Positron emission tomography with ^{18}fluorodeoxyglucose is reported to have high sensitivity (94%) and specificity (73%) for the diagnosis of AD as confirmed by histopathologic evaluation (Silverman 2004; Silverman et al 2001).

Positron emission tomography with ^{18}fluorodeoxyglucose has also been reported to detect differences in metabolic activity in patients with MCI with greater than 80% accuracy (Silverman 2004). In one study, patients who were diagnosed with AD at 18 months postscan demonstrated reduced ^{18}fluorodeoxyglucose (FDG) uptake in the right temporoparietal cortex when compared with MCI patients who had not developed the disease at this time point (Chetelat et al 2003). Additionally, FDG-PET may allow for assessment of the rate of progression of the disease on an individual basis (Silverman 2004).

Differences in metabolic activity have also been reported in "at risk" subjects. A study by Reiman et al (1996) investigated changes in glucose metabolism using FDG-PET in cognitively healthy late middle-aged adults who were homozygous for the ApoE ε4 allele and young adults (20–39) who are heterozygous for the ε4 allele. They found significant reductions in metabolism in the posterior cingulate (area of greatest reduction), parietal, temporal, and prefrontal brain in these subjects but not control subjects, consistent with findings from patients with probable AD (Reiman et al 1996, 1998).

Positron emission tomography with ^{18}fluorodeoxyglucose has demonstrated the ability to detect consistent differences in glucose metabolism in patients with AD versus control subjects, as well as to detect early changes in patients with MCI and individuals at higher risk for developing the disease. In the United States, the Center for Medicare and Medicaid Services (CMS) recently reversed a prior decision and approved reimbursement for FDG-PET with significant limitations and restrictions. The prior rejection and the current restrictions imposed by CMS appear to have been primarily based on the lack of effective therapies.

Structural MRI

Structural MRI has been utilized to rule out treatable or alternative causes for the presence of cognitive impairment at the time of patient evaluation for AD. Because of the wide variation in brain gray and white matter volumes, single time point measurements show significant overlap in AD patients and healthy subjects. Thus, the sensitivity and specificity of a single MRI scan for AD is somewhat limited. However, serial imaging of individual patients has shown an amazing ability to track quantitatively the progression of the disease. Atrophy of the medial temporal lobe has been used as a biological marker of AD using MRI with 85% specificity in patients with mild AD (Scheltens et al 2002). Increased brain atrophy has also been observed in patients at risk for AD who later developed the disease, indicating structural MRI may aid in early diagnosis of the disease. A study by (Reiman et al 1998) found a decrease in hippocampal volume in individuals homozygous for the ε4 allele. These results did not reach significance, however, while changes in glucose metabolism were significant, indicating that changes in brain volume may represent a later marker of disease pathology.

In addition to structural imaging, MRI may allow for imaging of amyloid itself under certain conditions. Higuchi et al (2005) recently imaged amyloid plaques in transgenic mice using fluorine-19 (^{19}F) and ^{1}H signals to detect a Congo Red derivative. In addition, Sigurdsson et al (2004) recently imaged amyloid plaques in transgenic mice with MRI and a gadolinium contrast agent. Although these techniques are exciting, they may not be safe in human subjects since they require high doses (20 mg/kg) of the contrast agent.

The National Institute on Aging has undertaken a multisite study (Alzheimer's Disease Neuroimaging Initiative) to assess the efficacy of PET and MRI in measuring disease progression and function as surrogate end point measures in clinical trials of therapeutic agents for AD. This study includes individuals with normal cognition, MCI, and early AD, assessing changes over time in each of these groups utilizing imaging, neuropsychological testing, and biochemical markers. The results of this study should help determine the relative utility of FDG-PET and MRI as biomarkers of AD.

Discussion

Positron emission tomography radioligand imaging has extraordinary sensitivity compared with MRI methods, which are about 10^{-12} versus 10^{-4} mol, respectively. In addition, PET radioligands can specifically label a single protein, whereas FDG-PET provides more general measures of local neuronal activity. In light of these relative capabilities, PET amyloid imaging would appear to be the best method for diagnosis and use as a surrogate end point in clinical trials of antiamyloid therapies. In fact, the actual situation is far more complex than this initial impression. First of all, the amyloid cascade hypothesis is just that, i.e., a hypothesis. In addition, the sensitivity and specificity of amyloid imaging in AD are unknown, and a moderate number of cognitively intact individuals may have significant amyloid burden. Finally, the criteria for a surrogate end point are very rigorous, and it will take many years for amyloid imaging to achieve, if ever, the status of a validated surrogate end point. The value of imaging the plaques themselves is questionable given their relative importance to oli-

gomers and the presence of plaques in "healthy" human brain. Because of these concerns, others modalities like FDG-PET and structural MRI may provide a more appropriate and global level of measurement to diagnose the disorder and to monitor the overall effect of novel therapies on neuronal activity and cognitive performance, including those designed to reduce amyloid burden. In contrast to the naïve initial impression, it may be more prudent to summarize the status of amyloid imaging as an exciting opportunity to explore pathophysiology and to examine critical hypotheses in the field.

Agdeppa ED, Kepe V, Liu J, Flores-Torres S, Satyamurthy N, Petric A, et al (2001): Binding characteristics of radiofluorinated 6-dialkylamino-2-naphthylethylidene derivatives as positron emission tomography imaging probes for beta-amyloid plaques in Alzheimer's disease. *J Neurosci* 21:RC189.

Agdeppa ED, Kepe V, Petri A, Satyamurthy N, Liu J, Huang SC, et al (2003): In vitro detection of (S)-naproxen and ibuprofen binding to plaques in the Alzheimer's brain using the positron emission tomography molecular imaging probe 2-(1-[6-[(2-[(18)F]fluoroethyl)(methyl)amino]-2-naphthyl]ethylidene)malono nitrile. *Neuroscience* 117:723–730.

Aisen PS, Schafer KA, Grundman M, Pfeiffer E, Sano M, Davis KL, et al (2003): Effects of rofecoxib or naproxen vs placebo on Alzheimer disease progression: A randomized controlled trial. *JAMA* 289:2819–2826.

Beffert U, Danik M, Krzywkowski P, Ramassamy C, Berrada F, Poirier J (1998): The neurobiology of apolipoproteins and their receptors in the CNS and Alzheimer's disease. *Brain Res Brain Res Rev* 27:119–142.

Braak H, Braak E (1997): Frequency of stages of Alzheimer-related lesions in different age categories. *Neurobiol Aging* 18:351–357.

Chetelat G, Desgranges B, de la Sayette V, Viader F, Eustache F, Baron JC (2003): Mild cognitive impairment: Can FDG-PET predict who is to rapidly convert to Alzheimer's disease? *Neurology* 60:1374–1377.

Corder EH, Saunders AM, Strittmatter WJ, Schmechel DE, Gaskell PC, Small GW, et al (1993): Gene dose of apolipoprotein E type 4 allele and the risk of Alzheimer's disease in late onset families. *Science* 261:921–923.

Cummings BJ, Cotman CW (1995): Image analysis of beta-amyloid load in Alzheimer's disease and relation to dementia severity. *Lancet* 346:1524–1528.

Dominguez DI, De Strooper B (2002): Novel therapeutic strategies provide the real test for the amyloid hypothesis of Alzheimer's disease. *Trends Pharmacol Sci* 23:324–330.

Edbauer D, Winkler E, Regula JT, Pesold B, Steiner H, Haass C (2003): Reconstitution of gamma-secretase activity. *Nat Cell Biol* 5:486–488.

Farrer LA, Cupples LA, Haines JL, Hyman B, Kukull WA, Mayeux R, et al (1997): Effects of age, sex, and ethnicity on the association between apolipoprotein E genotype and Alzheimer disease. A meta-analysis. APOE and Alzheimer Disease Meta Analysis Consortium. *JAMA* 278:1349–1356.

Farris W, Mansourian S, Chang Y, Lindsley L, Eckman EA, Frosch MP, et al (2003): Insulin-degrading enzyme regulates the levels of insulin, amyloid beta-protein, and the beta-amyloid precursor protein intracellular domain in vivo. *Proc Natl Acad Sci U S A* 100:4162–4167.

Fleming TR, DeMets DL (1996): Surrogate end points in clinical trials: Are we being misled? *Ann Intern Med* 125:605–613.

Fox NC, Black RS, Gilman S, Rossor MN, Griffith SG, Jenkins L, et al (2005): Effects of Abeta immunization (AN1792) on MRI measures of cerebral volume in Alzheimer disease. *Neurology* 64:1563–1572.

Ghebremedhin E, Schultz C, Braak E, Braak H (1998): High frequency of apolipoprotein E epsilon4 allele in young individuals with very mild Alzheimer's disease-related neurofibrillary changes. *Exp Neurol* 153:152–155.

Gomez-Isla T, West HL, Rebeck GW, Harr SD, Growdon JH, Locascio JJ, et al (1996): Clinical and pathological correlates of apolipoprotein E epsilon 4 in Alzheimer's disease. *Ann Neurol* 39:62–70.

Gotz J, Streffer JR, David D, Schild A, Hoerndli F, Pennanen L, et al (2004): Transgenic animal models of Alzheimer's disease and related disorders: Histopathology, behavior and therapy. *Mol Psychiatry* 9:664–683.

Guillozet AL, Weintraub S, Mash DC, Mesulam MM (2003): Neurofibrillary tangles, amyloid, and memory in aging and mild cognitive impairment. *Arch Neurol* 60:729–736.

Hardy J, Selkoe DJ (2002): The amyloid hypothesis of Alzheimer's disease: Progress and problems on the road to therapeutics. *Science* 297:353–356.

Hardy JA, Higgins GA (1992): Alzheimer's disease: The amyloid cascade hypothesis. *Science* 256:184–185.

Hebert LE, Scherr PA, Bienias JL, Bennett DA, Evans DA (2003): Alzheimer disease in the US population: Prevalence estimates using the 2000 census. *Arch Neurol* 60:1119–1122.

Higuchi M, Iwata N, Matsuba Y, Sato K, Sasamoto K, Saido TC (2005): 19F and 1H MRI detection of amyloid beta plaques in vivo. *Nat Neurosci* 8:527–533.

Hilts J (2003): *Protecting America's Health: The FDA, Business, and 100 years of Regulation*. New York: Knopf.

Hock C, Konietzko U, Streffer JR, Tracy J, Signorell A, Muller-Tillmanns B, et al (2003): Antibodies against beta-amyloid slow cognitive decline in Alzheimer's disease. *Neuron* 38:547–554.

Janus C, Pearson J, McLaurin J, Mathews PM, Jiang Y, Schmidt SD, et al (2000): A beta peptide immunization reduces behavioural impairment and plaques in a model of Alzheimer's disease. *Nature* 408:979–982.

Klein WL, Krafft GA, Finch CE (2001): Targeting small Abeta oligomers: The solution to an Alzheimer's disease conundrum? *Trends Neurosci* 24:219–224.

Klunk WE, Engler H, Nordberg A, Wang Y, Blomqvist G, Holt DP, et al (2004a): Imaging brain amyloid in Alzheimer's disease with Pittsburgh Compound-B. *Ann Neurol* 55:306–319.

Klunk WE, Price JC, Lopresti BJ, Debnath ML, Holt DP, Wang Y, et al (2004b): Human amyloid-imaging studies in controls, mild cognitive impairment, and Alzheimer's disease using Pittsburgh Compound B. *Neurobiol Aging* 25:S58.

Kung MP, Hou C, Zhuang ZP, Skovronsky DM, Kung HF (2004): Binding of two potential imaging agents targeting amyloid plaques in Alzheimer's disease brain. *Neurobiol Aging* 25:S57.

Lewis J, Dickson DW, Lin WL, Chisholm L, Corral A, Jones G, et al (2001): Enhanced neurofibrillary degeneration in transgenic mice expressing mutant tau and APP. *Science* 293:1487–1491.

Lockhart A, Ye L, Judd DB, Merritt AT, Lowe PN, Morgenstern JL, et al (2005): Evidence for the presence of three distinct binding sites for the thioflavin T class of Alzheimer's disease PET imaging agents on beta-amyloid peptide fibrils. *J Biol Chem* 280:7677–7684.

Lue LF, Kuo YM, Roher AE, Brachova L, Shen Y, Sue L, et al (1999): Soluble amyloid beta peptide concentration as a predictor of synaptic change in Alzheimer's disease. *Am J Pathol* 155:853–862.

Mann DM, Iwatsubo T, Pickering-Brown SM, Owen F, Saido TC, Perry RH (1997): Preferential deposition of amyloid beta protein (Abeta) in the form Abeta40 in Alzheimer's disease is associated with a gene dosage effect of the apolipoprotein E E4 allele. *Neurosci Lett* 221:81–84.

Mathis CA, Wang Y, Holt DP, Huang GF, Debnath ML, Klunk WE (2003): Synthesis and evaluation of 11C-labeled 6-substituted 2-arylbenzothiazoles as amyloid imaging agents. *J Med Chem* 46:2740–2754.

Mathis CA, Wang Y, Klunk WE (2004): Imaging beta-amyloid plaques and neurofibrillary tangles in the aging human brain. *Curr Pharm Des* 10:1469–1492.

McGeer PL, Schulzer M, McGeer EG (1996): Arthritis and anti-inflammatory agents as possible protective factors for Alzheimer's disease: A review of 17 epidemiologic studies. *Neurology* 47:425–432.

McLean CA, Cherny RA, Fraser FW, Fuller SJ, Smith MJ, Beyreuther K, et al (1999): Soluble pool of Abeta amyloid as a determinant of severity of neurodegeneration in Alzheimer's disease. *Ann Neurol* 46:860–866.

Mintun MA, Sheline YI, Mach RH, Dence CS, Lee SY, Rundle MM, et al (2004): *Quantitative Discrimination of Alzheimer's Disease from Aging with Cerebral Amyloid Imaging.* San Diego: Society for Neuroscience.

Mucke L, Masliah E, Yu GQ, Mallory M, Rockenstein EM, Tatsuno G, et al (2000): High-level neuronal expression of abeta 1-42 in wild-type human amyloid protein precursor transgenic mice: Synaptotoxicity without plaque formation. *J Neurosci* 20:4050–4058.

Mudher A, Lovestone S (2002): Alzheimer's disease– do tauists and baptists finally shake hands? *Trends Neurosci* 25:22–26.

Naslund J, Haroutunian V, Mohs R, Davis KL, Davies P, Greengard P, et al (2000): Correlation between elevated levels of amyloid beta-peptide in the brain and cognitive decline. *JAMA* 283:1571–1577.

Nicoll JA, Wilkinson D, Holmes C, Steart P, Markham H, Weller RO (2003): Neuropathology of human Alzheimer disease after immunization with amyloid-beta peptide: A case report. *Nat Med* 9:448–452.

Nunan J, Small DH (2002): Proteolytic processing of the amyloid-beta protein precursor of Alzheimer's disease. *Essays Biochem* 38:37–49.

Oddo S, Caccamo A, Shepherd JD, Murphy MP, Golde TE, Kayed R, et al (2003): Triple-transgenic model of Alzheimer's disease with plaques and tangles: Intracellular Abeta and synaptic dysfunction. *Neuron* 39:409–421.

Orgogozo JM, Gilman S, Dartigues JF, Laurent B, Puel M, Kirby LC, et al (2003): Subacute meningoencephalitis in a subset of patients with AD after Abeta42 immunization. *Neurology* 61:46–54.

Puglielli L, Tanzi RE, Kovacs DM (2003): Alzheimer's disease: The cholesterol connection. *Nat Neurosci* 6:345–351.

Ravina B, Eidelberg D, Ahlskog JE, Albin RL, Brooks DJ, Carbon M, et al (2005): The role of radiotracer imaging in Parkinson disease. *Neurology* 64:208–215.

Reiman EM, Caselli RJ, Yun LS, Chen K, Bandy D, Minoshima S, et al (1996): Preclinical evidence of Alzheimer's disease in persons homozygous for the epsilon 4 allele for apolipoprotein E. *N Engl J Med* 334:752–758.

Reiman EM, Uecker A, Caselli RJ, Lewis S, Bandy D, de Leon MJ, et al (1998): Hippocampal volumes in cognitively normal persons at genetic risk for Alzheimer's disease. *Ann Neurol* 44:288–291.

Reines SA, Block GA, Morris JC, Liu G, Nessly ML, Lines CR, et al (2004): Rofecoxib: No effect on Alzheimer's disease in a 1-year, randomized, blinded, controlled study. *Neurology* 62:66–71.

Scheltens P, Fox N, Barkhof F, De Carli C (2002): Structural magnetic resonance imaging in the practical assessment of dementia: Beyond exclusion. *Lancet Neurol* 1:13–21.

Schenk D, Barbour R, Dunn W, Gordon G, Grajeda H, Guido T, et al (1999): Immunization with amyloid-beta attenuates Alzheimer-disease-like pathology in the PDAPP mouse. *Nature* 400:173–177.

Selkoe DJ (2004): Alzheimer disease: Mechanistic understanding predicts novel therapies. *Ann Intern Med* 140:627–638.

Shoghi-Jadid K, Barrio JR, Kepe V, Wu HM, Small GW, Phelps ME, et al (2005): Imaging beta-amyloid fibrils in Alzheimer's disease: A critical analysis through simulation of amyloid fibril polymerization. *Nucl Med Biol* 32: 337–351.

Shoghi-Jadid K, Small GW, Agdeppa ED, Kepe V, Ercoli LM, Siddarth P, et al (2002): Localization of neurofibrillary tangles and beta-amyloid plaques in the brains of living patients with Alzheimer disease. *Am J Geriatr Psychiatry* 10:24–35.

Sigurdsson EM, Wadghiri YZ, Blind JA, Knudsen E, Asuni A, Sadowski M, et al (2004): In vivo magnetic resonance imaging of amyloid plaques in mice with a non-toxic Aβ derivative. *Neurobiol Aging* 25:S57.

Silverman DH (2004): Brain 18F-FDG PET in the diagnosis of neurodegenerative dementias: Comparison with perfusion SPECT and with clinical evaluations lacking nuclear imaging. *J Nucl Med* 45:594–607.

Silverman DH, Small GW, Chang CY, Lu CS, Kung De Aburto MA, Chen W, et al (2001): Positron emission tomography in evaluation of dementia: Regional brain metabolism and long-term outcome. *JAMA* 286:2120–2127.

Small GW, Kepe V, Huang SC, Wu HM, Ercoli L, Siddarth P, et al (2004): Plaques and tangle imaging using [F-18]FDDNP-PET differentiates Alzheimer's disease, mild cognitive impairment, and older controls. *Neurobiol Aging* 25:S58.

Sommer B (2002): Alzheimer's disease and the amyloid cascade hypothesis: Ten years on. *Curr Opin Pharmacol* 2:87–92.

Szekely CA, Thorne JE, Zandi PP, Ek M, Messias E, Breitner JC, et al (2004): Nonsteroidal anti-inflammatory drugs for the prevention of Alzheimer's disease: A systematic review. *Neuroepidemiology* 23:159–169.

Verhoeff NP, Wilson AA, Takeshita S, Trop L, Hussey D, Singh K, et al (2004): In-vivo imaging of Alzheimer disease beta-amyloid with [11C]SB-13 PET. *Am J Geriatr Psychiatry* 12:584–595.

Weggen S, Eriksen JL, Das P, Sagi SA, Wang R, Pietrzik CU, et al (2001): A subset of NSAIDs lower amyloidogenic Abeta42 independently of cyclooxygenase activity. *Nature* 414:212–216.

Wilcock GK, Esiri MM (1982): Plaques, tangles and dementia. A quantitative study. *J Neurol Sci* 56:343–356.

Ye L, Morgenstern JL, Gee AD, Hong G, Brown J, Lockhart A (2005): Delineation of PET imaging agent binding sites on beta -amyloid peptide fibrils. *J Biol Chem* 280(25):23599–23604.

Zhou Y, Su Y, Li B, Liu F, Ryder JW, Wu X, et al (2003): Nonsteroidal anti-inflammatory drugs can lower amyloidogenic Abeta42 by inhibiting Rho. *Science* 302:1215–1217.