Childhood-Onset Schizophrenia: Progressive Brain Changes during Adolescence

Jay N. Giedd, Neal O. Jeffries, Jonathan Blumenthal, F.X. Castellanos, Anna C. Vaituzis, Thomas Fernandez, Susan D. Hamburger, Hong Liu, Jean Nelson, Jeff Bedwell, Lan Tran, Marge Lenane, Rob Nicolson, and Judith L. Rapoport

Background: *Previous NIMH childhood onset schizophrenia (COS) anatomic brain MRI studies found progression of ventricular volume and other structural brain anomalies at 2-year follow up across mean ages 14 to 16 years. However, studies in adult patients generally do not show progression of ventricular volume or correlation of ventricular volume with duration of illness. To address issues of progression of brain anomalies in schizophrenia, this report extends previous studies to include a third longitudinal scan, uses a larger sample size, and includes measures of the amygdala and hippocampus.*

Methods: *Volumes of the total cerebrum, lateral ventricles, hippocampus, and amygdala were quantified on 208 brain magnetic resonance imaging scans from 42 adolescents with COS (23 with one or more repeat scan) and 74 age- and gender-matched controls (36 with one or more repeat scan). A statistical technique permitting combined use of cross-sectional and longitudinal data was used to assess age-related changes, linearity, and diagnostic group differences.*

Results: *Differential nonlinear progression of brain anomalies was seen during adolescence with the total cerebrum and hippocampus decreasing and lateral ventricles increasing in the COS group. The developmental curves for these structures reached an asymptote by early adulthood for the COS group and did not significantly change with age in the control group.*

Conclusions: *These findings reconcile less striking progression of anatomic brain images usually seen for adult schizophrenia and complement other data consistent with time-limited, diagnostic-specific decreases in brain tissue. Adolescence appears to be a unique period of differential brain development in schizophrenia.* Biol Psychiatry 1999; 46:892–898 © *1999 Society of Biological Psychiatry*

From the Child Psychiatry Branch of the National Institute of Mental Health, Bethesda, MD.

Address reprint requests to Jay N. Giedd, MD, Child Psychiatry Branch, National Institute of Mental Health, Building 10, Room 4C110, 10 Center Drive MSC 1367, Bethesda, MD 20892.

Received November 30, 1998; revised March 16, 1999; accepted March 17, 1999.

Key Words: Brain, MRI, longitudinal, child, adolescence, schizophrenia

Introduction

Brain imaging studies of adult schizophrenia patients have usually found slightly decreased total brain volume, enlarged ventricular volume, and smaller medial temporal lobe structures, particularly the hippocampus (Lawrie and Abukmeil 1998; Nelson et al 1998). These subtle findings are only seen with relatively large sample sizes, which may be why small-sample postmortem studies generally do not find significant differences in hippocampal volume (Dwork 1997; Heckers et al 1990).

Longitudinal imaging studies of subjects age 20 or older usually find no progression of these brain changes (Degreef et al 1992; DeLisi et al 1992; Illowsky et al 1988) or progression only for a subgroup (Gur et al 1998; Keshavan et al 1998), with some exceptions (Davis et al 1998; DeLisi et al 1997). However, considerable indirect evidence such as the larger extracerebral cerebral spinal fluid volume with normal skull size in schizophrenia (as reviewed by Woods 1998), as well as postmortem evidence of decreased neuropil in prefrontal, dorsolateral prefrontal, and occipital cortices, support a progressive loss of tissue volume having occurred at some point during postnatal development (Selemon and Goldman-Rakic 1999).

Childhood onset schizophrenia (COS), defined as onset of psychosis by age 12 years, has been shown by clinical, neuropsychological, brain imaging, and other neurobiologic studies to be continuous with the later onset disorder (Frazier et al 1996; Jacobsen et al 1998b); these patients resemble poor outcome adult cases with a more severe premorbid course (Asarnow et al 1994; Watkins et al 1988).

Previous NIMH COS imaging studies reported a differential decrease in thalamic and temporal lobe structures and a differential increase in ventricular volume at 2-year

© 1999 Society of Biological Psychiatry

0006-3223/99/$20.00
PII S0006-3223(99)00072-4

BIOL PSYCHIATRY
1999;46:892–898

follow up rescan (Jacobsen et al 1998a; Rapoport et al 1997); however, limitations of sample size and only two longitudinal data points precluded assessment of nonlinearity for these changes. The present report is an extension of these data with a larger sample size, utilization of both longitudinal and cross-sectional data, and extension for healthy and schizophrenic subjects to a third scan.

Based on our previous findings, we expected relative decreases in total cerebral volume and temporal lobe structures, and increase in ventricular volume. However, studies with adults finding less striking or minimal differential progression and a lack of correlation between brain volume decreases and age of onset (Lim et al 1996; Marsh et al 1994), suggest that this effect may dissipate during later adolescence.

Methods and Materials

Subjects

COS. Forty-two subjects, meeting unmodified DSM-IV criteria for schizophrenia with onset of psychosis before age 12, were recruited as part of an ongoing nationwide effort involving over 1000 chart reviews and 200 in-person screenings. As subjects were participating in an inpatient double-blind placebo-controlled cross-over study of atypical neuroleptics, failure to respond to typical neuroleptics was an inclusion criteria. All of the subjects were on atypical neuroleptics at follow up. Four of the subjects had a comorbid diagnosis of mild pervasive developmental disorder, NOS, only evident after effective treatment of schizophrenia. Further details of patient selection and characteristics are presented elsewhere (Kumra et al 1998; McKenna et al 1994).

CONTROL SUBJECTS. Seventy-four matched healthy subjects were drawn from on ongoing study of healthy brain development being conducted by the Child Psychiatry Branch of the National Institute of Mental Health. Strict inclusion criteria were established resulting in acceptance of approximately one in six initial volunteers, with the most common exclusion resulting from evidence of a psychiatric disorder in a first-degree relative. Details concerning phone assessment, information from schools and parents, and physical, neurological, psychiatric, and neuropsychologic testing are presented elsewhere (Giedd et al 1996a, 1997).

The NIMH Institutional Review Board approved the project. Written consent by the parents and assent by the child were obtained for all subjects and controls. All of the participants in this study agreed to participate in follow up scans at approximately 2-year intervals. All patient and controls with one or more measurable scans are subjects of these analyses.

Demographic characteristics for single and longitudinal scan subjects are presented in Table 1.

MRI Image Acquisition

All scans were obtained on the same GE 1.5 Tesla Signa scanner located at the Clinical Center of the NIH. Two-mm-thick coronal slices and 1.5-mm-thick axial slices were acquired using a three-dimensional spoiled gradient recalled echo in the steady state (time to echo = 5 msec, time to repeat = 24 msec, flip angle = 45 degrees, acquisition matrix = 192 × 256, number of excitations = 1, field of view = 24 cm^2, number of slices = 124). Vitamin E capsules, one taped to the left lateral inferior orbital ridge and one wrapped in gauze and placed in the meatus of each ear, were used to help standardize head placement by assuring that all three capsules appeared in the same axial slice of a multi-echo scout series. To standardize head position within the axial plane, patients were aligned so their nose was at the 12:00 position.

No sedation was used for the control subjects. Fifteen COS subjects at time one, 10 at time two, and 4 at time three were sedated with chloral hydrate, 0.5 to 2.0 g, or lorazepam, 1.0 to 2.0 mg.

Image Analysis

Scans were evaluated clinically by a neuroradiologist. Two control subjects were noted to have increased T2 signal intensities, one in the left semiovale and the other in the right parietal lobe. Both subjects were asymptomatic on clinical follow-up. Two COS subjects had reported ventriculomegaly. No other gross abnormalities were reported and all of these subjects were retained in the data set. All longitudinal scans were blinded and remeasured during the same period to minimize measurement error related to rater drift. The relative stability of brain structure measures from scans acquired at 2- to 4-week intervals, indicating that longitudinal changes reflect actual differences in brain morphometry and are not accounted for by variability related to scan acquisition, has been previously addressed (Giedd et al 1995).

Total Cerebral Volume Quantification

Total cerebral volume was quantified using a semi-automated program, which used successive iterations of an energy minimization function to enforce constraints on curvature and topology of a mathematically modeled template brain (Snell et al 1995). This technique allowed prior knowledge of brain anatomy contained in the template to supplement MRI signal intensity characteristics. Each axial slice of the brain was then edited by experienced raters to remove artifacts such as patches of dura or eyeball. Intraclass correlations for the volumes of the edited brains were .99 for inter-rater reliability (ACV and JNG) and .95 by comparison to volumes derived from more conventional slice by slice hand tracing through all axial slices on which brain matter is visible. Further details are provided elsewhere (Giedd et al 1996a).

Ventricular Volume Quantification

The imaging data were imported into an image analysis program developed at the NIH (Rasband 1993). Lateral ventricular volumes were measured in the coronal plane on all slices on which they were visible using an operator-supervised thresholding technique, which segmented cerebrospinal fluid from brain tissue. Because this process required little subjectivity, inter-rater reliability was extremely high (ICC = .99).

Amygdala/Hippocampal Formation Quantification

Measures of the amygdala and hippocampal formation were obtained by manual tracing in the coronal plane by a single

Table 1A. Demographics of Childhood-Onset Schizophrenia (COS) and Healthy Control Subjects at Initial Scan

	Control subjects	COS	t or χ^2	p value
Number	74	42		
Gender	44 M/30 F	23 M/19 F	.24[a]	.623
Age (years)	13.8 (2.5)	14.4 (2.3)	−1.24	.22
Height (inches)	63.6 (5.5)	62.8 (4.4)	.79	.43
Weight (pounds)	116.7 (29.8)	131.8 (36.5)	−2.39	.02
% Right-handed	85	81	.34[a]	.56
SANS	NA	61.2 (27.6)		
SAPS	NA	43.9 (18.7)		
BPRS	NA	49 (12.1)		

Table 1B. Demographics of COS and Healthy Control Subjects with Longitudinal Scans

	Time 1		Time 2		Time 3	
	Control subjects	COS	Control subjects	COS	Control subjects	COS
Number	36	23	36	23	19	14
Gender	23 M/13 F	11 M/12 F	23 M/13 F	11 M/12 F	12 M/7 F	7 M/7 F
Age (years)	13.6 (2.6)	14.8 (2.5)	16.2 (3.1)	17.0 (2.5)	18.0 (3.0)	19.4 (1.5)
Height (inches)	63.8 (6.1)	63.8 (3.8)	66.8 (5.3)	65.6 (4.0)	67.8 (4.2)	67.0 (4.5)
Weight (pounds)	113.8 (31.2)	138.5 (39.3)	136.8 (32.2)	171.0 (41.6)	141.4 (24.6)	184.5 (37.3)
% Right-handed	86	87	86	87	82	73
SANS	NA	71.7 (20.2)	NA	61.2 (25.1)	NA	39.8 (30.2)
SAPS	NA	49.1 (19.1)	NA	22.7 (16.1)	NA	27.0 (20.4)
BPRS	NA	52.1 (9.1)	NA	37.8 (7.4)	NA	35.8 (11.8)

[a]Chi square with 1 degree of freedom.
SANS, Scale for the Assessment of Negative Symptoms; SAPS, Scale for the Assessment of Positive Symptoms; BPRS, Brief Psychiatric Rating Scale.

experienced rater (ACV) blind to any subject characteristics (Giedd et al 1996b). Even at a histologic level precise delineation of the amygdala/hippocampal boundary can be difficult (Bergin et al 1994). Our measurement of the hippocampal formation includes the cornu ammonis, dentate gyrus, and subiculum. Each of these components have different histologic characteristics and topographically well-ordered afferents and efferents (Nolte 1993), however the resolution of our images was not sufficient to quantify each separately. The amygdala and hippocampus were quantified by manual tracing in the coronal plane with the slice containing the most anterior portions of the mammillary bodies used as the most anterior portion of the hippocampus (inclusive) (Bogerts et al 1993; Shenton et al 1992). The posterior boundary of the hippocampal formation was the most posterior slice in which fibers of the fornix were visible (Cook et al 1992; Shenton et al 1992). The anterior boundary of the amygdala was the most anterior slice on which it appeared and the posterior boundary was the most posterior slice anterior to the mammillary bodies.

Reliabilities for the quantification of each of the structures were established by having two raters (ACV and JNG) initially measure ten subjects twice to determine intra-rater and inter-rater intraclass correlation coefficients (ICCs) and then blindly introducing previously measured scans throughout the analysis to account for possible drifts in rater assessment. Intra-rater ICCs were .86 for the amygdala and .87 for the hippocampus.

An assessment of the effectiveness of the vitamin E aided standardization of head positioning at the time of acquisition was conducted because this method of quantification is potentially vulnerable to differences in head positioning. Analysis of the angle of a line intersecting the anterior and posterior commissures to the x–y plane by the Wilcoxon rank sums tests revealed no head position differences between groups or across time.

Symptom Assessment

COS subjects' clinical symptoms were rated with the Brief Psychiatric Rating Scale (BPRS); (Overall et al 1961), the Scale for the Assessment of Positive Symptoms (SAPS); (Andreasen 1984), and the Scale for the Assessment of Negative Symptoms (SANS); (Andreasen 1983).

Statistical Analysis

Demographic variable differences were examined with t tests. Brain structure differences were analyzed with ANOVA and ANCOVA, adjusting for total cerebral volume. Change scores for brain imaging variables (the most recent scan minus the initial scan) were correlated with the corresponding BPRS, SANS, and SAPS change scores.

To analyze growth or decline with age, we employed a method that permits the combined use of cross-sectional and longitudinal data. The method is a modification of that described in Section 1.4 of Diggle and co-workers (Diggle et al 1994), with the inclusion of a quadratic term to assess nonlinear longitudinal growth (Ware et al 1990). While there are many types of nonlinear, parametric growth patterns (e.g., cubic or higher order

BIOL PSYCHIATRY
1999;46:892–898

Table 2. Estimated Coefficients of the Model[a]

	Control subjects				Childhood onset schizophrenia (COS)			
			Wald test that $B_1 = 0$ and $B_2 = 0$				Wald test that $B_1 = 0$ and $B_2 = 0$	
	B_1	B_2	χ^2 (df = 2)	p value	B_1	B_2	χ^2 (df = 2)	p value
Total cerebrum[b]	10.8 (7.2)	−2.4 (1.6)	2.3	.32	−29.7 (6.2)	2.2[c] (1.1)	37.2	<.0001
Lateral ventricle[b]	0.33 (.40)	0.04 (.08)	0.89	.64	3.0 (.41)	−0.3[c] (.06)	66.8	<.0001
Hippocampus[b]	−0.04 (.13)	0.01 (.03)	0.75	.69	−0.4 (.11)	0.05[c] (.02)	18.8	.0002
Amygdala	0.20 (.12)	−0.04 (.25)	3.5	.17	0.04 (.10)	0.01 (.02)	4.4	.12

[a]$Size_j - Size_1 = B_0 + B_1 \times (age_j - age_1) + B_2 \times (age_j - age_1)^2 + (\epsilon_j - \epsilon_1)$ for the total cerebrum, lateral ventricle, hippocampus, and amygdala for scans from COS ($n = 42$) and matched control subjects ($n = 74$). Standard errors for estimated B_1 and B_2 are in parentheses.

[b]Significant diagnostic differences for total cerebrum ($\chi^2 = 28.9$, $p < .0001$), lateral ventricle ($\chi^2 = 33.4$, $p < .0001$), and hippocampus ($\chi^2 = 13.7$, $p = .002$).

[c]Significant nonlinearity of developmental curves for total cerebrum ($Z = 2.0$, $p = .05$), lateral ventricle ($Z = -4.3$, $p < .0001$), and hippocampus ($Z = 2.5$, $p = .01$). Z statistics computed by dividing B_2 estimate by its standard error.

polynomial, monomolecular exponential) the quadratic form was chosen because it provides a reasonable compromise between parsimony and complexity. For most of the structures studied here, a linear or constant model clearly fails to capture important aspects of change over time. The quadratic models are perhaps the simplest (in terms of having few parameters to estimate), which seem to adequately describe the observed data. Intra-individual dependence was modeled through an exponential correlation structure that recognizes that an individual's measures are more closely correlated when they are taken closer together in time. Individual specific random effects were also incorporated to allow each person to have a different intercept for their growth curve.

To characterize age-related changes in brain morphometry the following longitudinal growth model was used:

$$Size_j - Size_1 = B_0 + B_1 \times (age_j - age_1) + B_2 \times (age_j - age_1)^2 + \epsilon_j - \epsilon_1)$$

Where j indicates a measurement after the first, e.g., j = 2 indicates the second measurement. ϵ_j and ϵ_1 are assumed to have a normal distribution with mean 0 and exponential correlation function, $\sigma^2 \exp(-(time_j - time_1)^2/\rho^2)$, with σ and ρ parameters to be estimated.

The inclusion of the squared term means this relationship is nonlinear if the regression coefficient, B_2, is significantly different from zero. The constant, B_0, varies by individual and depends on the person's age when first measured (age_1) and their gender, and also includes a random effects component. The B_1 and B_2 estimates are the same for those individuals in a given diagnostic group. Separate estimates of B_1 and B_2 were made for each diagnostic group.

A Wald statistic (having a χ^2 distribution with 2 degrees of freedom) was used to assess whether the B_1 and B_2 coefficients for a given diagnostic group are simultaneously zero (rationale for Wald tests are given in Section 5.3.3 of Diggle et al 1994). In this context, a large Wald statistic indicates linear or quadratic age-related development. If the Wald statistic indicates some change occurs over time, the estimate of B_2 is examined to determine if the change is linear or nonlinear (quadratic). Evidence of nonlinear change is given by an estimate of B_2 that is significantly different than zero.

To address the question of diagnostic differences in the patterns of change, a second Wald test (also having a χ^2 distribution with 2 degrees of freedom) was used to test whether the B_1 and B_2 coefficients were the same for the schizophrenia and control groups.

Laterality

Laterality was assessed using an asymmetry index defined as ln (right measure/left measure), i.e., the natural logarithm of the ratio of the size of the right side structure divided by the size of the left side structure. Our asymmetry index is a close approximation to 2*[(right − left)/(right + left)] but is slightly more robust to extreme values and hence, has a slightly lower variance. The effects of diagnosis on laterality were addressed by a t test comparing the asymmetry indexes of the two groups.

Results

As seen in Table 1A subjects and control subjects were well matched for gender, age, and height but not for weight (presumably secondary to neuroleptic effects). Also, as seen in Table 1B, the COS subjects were considerably clinically improved on rescan but still symptomatic.

At initial scan, total cerebral volume was smaller for patients ($t = 2.3$, df = 111, $p = .02$) and lateral ventricular volume was larger ($t = 3.0$, df = 111, $p = .003$). There were no significant differences in amygdala or hippocampal volumes, with or without ANCOVA adjustment for total cerebral volume.

For the COS group, but not for the control subjects, significant age-related changes were noted for volume of the total cerebrum ($\chi^2 = 37.2$, $p < .0001$), lateral ventricles ($\chi^2 = 66.8$, $p < .0001$), and hippocampus ($\chi^2 = 18.8$, $p = .0002$) (see Table 2). The developmental

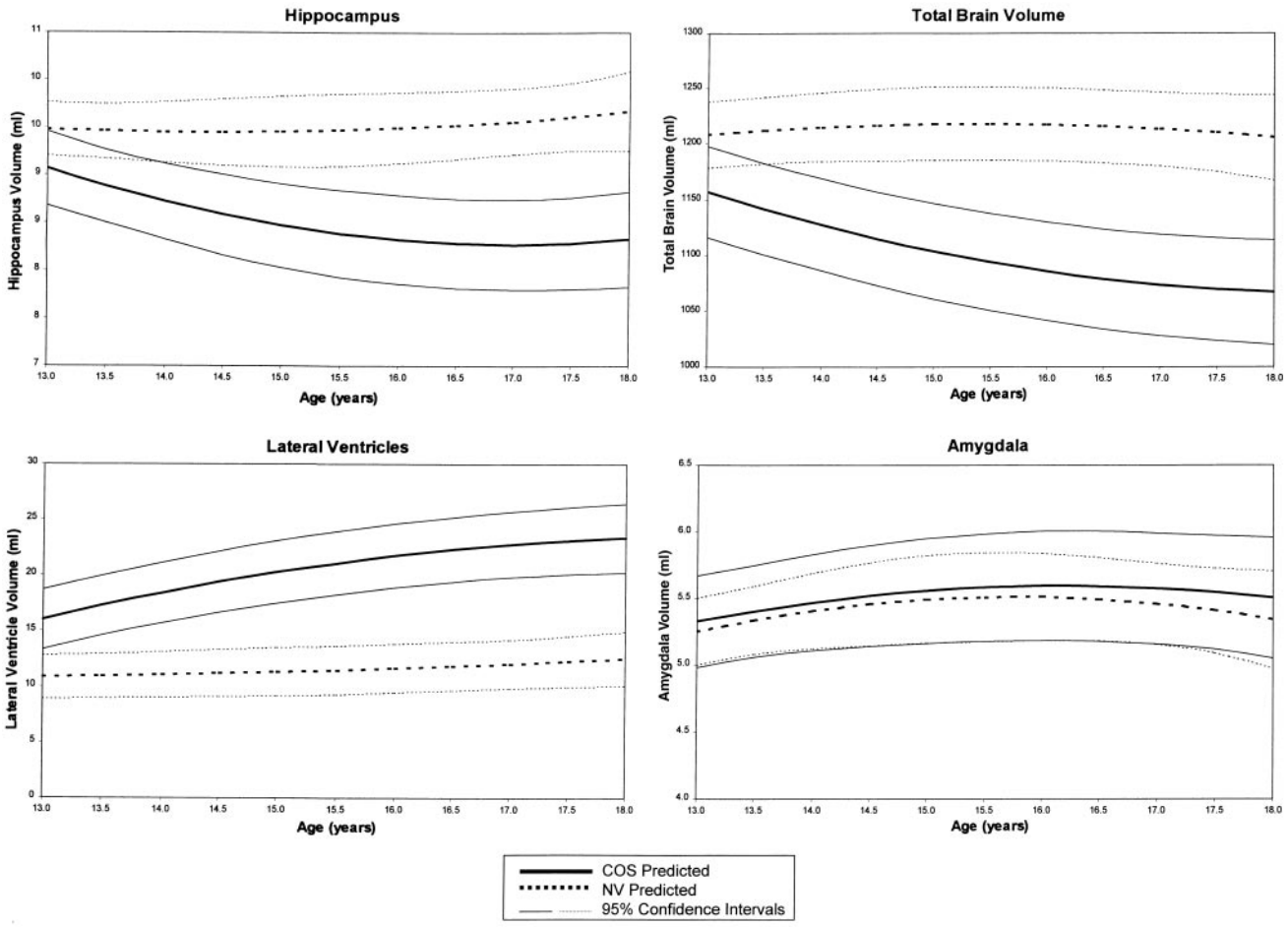

Figure 1. Brain MRI measures for childhood onset schizophrenia (COS) patients ($n = 42$) and healthy control subjects ($n = 74$) during adolescence: combined cross-sectional and longitudinal data. For the COS group, the developmental curves for volumes of the total cerebrum, ventricles, and hippocampus change significantly with age, are nonlinear, and are different from the control curves, which do not show age-related effects.

curves (i.e., B_1 and B_2 coefficients) for each of these structures differed significantly between the COS and control groups ($\chi^2 = 28.9$, $p < .0001$, $\chi^2 = 33.4$, $p < .0001$, and $\chi^2 = 13.7$, $p = .002$ for the total cerebrum, lateral ventricle, and hippocampus, respectively). Amygdala volume did not change with age for either group. Analysis of the B_2 coefficient indicates that the COS age-related changes were significantly nonlinear and as seen in Figure 1, seem to asymptote as subjects approach adulthood.

COS subjects differed significantly from control subjects in terms of weight ($t = 2.39$, $p = .02$), but not age, height, gender, or handedness (see Table 1). There were no significant effects of diagnosis on asymmetry index for any structure.

Correlation with Clinical Variables

For the schizophrenics for whom 3 to 5 year follow up scans were available, there was a significant correlation between change in ventricular volume and change in the SANS ($n = 13$, $r = .57$, $p = .04$) and between change in the hippocampus and change in the SAPS ($n = 13$, $r = -.34$, $p = .02$).

Discussion

This study extends prior reports of differential progression of brain changes during adolescence in COS for total cerebrum, lateral ventricle, and hippocampal volumes. The availability of a larger sample size and a third longitudinal data point for many of the subjects allowed us to characterize the nonlinear nature of these differential progressions, demonstrating that the changes taper off as subjects approach adulthood. This is a critical point for reconciling findings such as the lack of correlation between age of onset and duration of illness and decreases in brain tissue seen in adult schizophrenics (Lim et al 1996; Marsh et al 1994). It was also evident that the

differential progressions seen during early adolescence could not continue in a linear fashion without gross neurologic impairment. The leveling off of change in cerebral, ventricular, and hippocampal volumes as subjects approach adulthood highlights the uniqueness of adolescence as a time of accelerated brain development with vigorous synaptic pruning (Huttenlocher 1984) and metabolic changes (Chugani et al 1991). These findings are supported by indirect evidence from skull and cerebral spinal fluid volume measures (Woods 1998) and postmortem histologic studies (Selemon and Goldman-Rakic 1999), which all can be accounted for by a time-limited, postnatal period of progressive tissue loss.

Limitations of the study include the confounds of medication exposure (possibly with a unique adolescent brain development interaction), IQ and socioeconomic status, a weight difference between the groups, a change in the percentage of nonright-handers from scan two to scan three in the COS group, and a greater degree of motion artifact on scans in the COS group. The fact that the COS group consists of subjects who had not responded to typical neuroleptics also limits the ability to generalize the findings.

Hippocampal volume decline also followed a nonlinear developmental path in COS. While there are methodologic concerns such as the difficulty of precisely quantifying the structure or the possibility that subtle changes in MRI acquisition technology may affect quantification, it is difficult to see how this would account for diagnostic differences. These changes are of interest as hippocampal size is particularly sensitive to the effects of stress, with smaller volumes seen in post-traumatic stress disorder (Bremner et al 1995, 1997) and affective disorders (Sheline 1998). A possible mechanism for decrease in hippocampal volume is neuronal or glial cell loss secondary to hypercortisolemia, which increases vulnerability to glutamate neurotoxicity (Sheline 1998). Whether the noted changes in hippocampal volume represent indirect effects related to the stress of the illness, or are more direct effects of the schizophrenic process, can not be determined from this study. The relative stability of amygdala and superior temporal gyrus size provide an important contrast lending credibility to the hippocampal findings.

This work does not contradict most neurodevelopmental models of schizophrenia. In fact, these COS subjects had a higher incidence of speech and motor abnormalities prior to the onset of psychosis (Alaghband-Rad et al 1997), implicating greater deviance of still earlier brain development abnormalities. Also, these brain morphometric changes were only noted for the patients years after the onset of psychosis (mean age = 10 years) and thus do not directly address the issue of "triggers" for schizophrenia.

The relationship between changes in clinical severity and brain structures is intriguing but the small sample for whom longitudinal data is available limits interpretation of these associations. If replicated, these findings have implications for future treatment monitoring.

In summary, differential asymptotic developmental curves during adolescence in COS add to the previous indirect evidence for abnormal postnatal brain development in schizophrenia. Adolescence provides a unique window of opportunity to study late brain changes in this disorder. Putative etiologic and physiologic models of schizophrenia need to take both early and late changes into account.

This work was presented at the conference, Schizophrenia: From Molecule to Public Policy, held in Santa Fe, New Mexico in October 1998. The conference was sponsored by the Society of Biological Psychiatry through an unrestricted educational grant provided by Eli Lilly and Company.

References

Alaghband-Rad J, Hamburger SD, Giedd JN, Frazier JA, Rapoport JL (1997): Childhood-onset schizophrenia: Biological markers in relation to clinical characteristics. *Am J Psychiatry* 154:64–68.

Andreasen NC (1983): *The Scale for the Assessment of Negative Symptoms (SANS).* Iowa City, Iowa:University of Iowa.

Andreasen NC (1984): *The Scale for the Assessment of Positive Symptoms (SAPS).* Iowa City, Iowa:University of Iowa.

Asarnow RF, Asamen J, Granholm E, Sherman T, Watkins JM, Williams ME (1994): Cognitive/neuropsychological studies of children with a schizophrenic disorder. *Schizophr Bull* 20:647–669.

Bergin PS, Raymond AA, Free SL, Sisodiya SM, Stevens JM (1994): Magnetic resonance volumetry. *Neurology* 44:1770–1771.

Bogerts B, Lieberman JA, Ashtari M, Bilder RM, Degreef G, Lerner G, et al (1993): Hippocampus-amygdala volumes and psychopathology in chronic schizophrenia. *Biol Psychiatry* 33:236–246.

Bremner JD, Randall P, Scott TM, Bronen RA, Seibyl JP, Southwick SM, (1995): MRI-based measurement of hippocampal volume in patients with combat-related posttraumatic stress disorder. *Am J Psychiatry* 152:973–981.

Bremner JD, Randall P, Vermetten E, Staib L, Bronen RA, Mazure C, et al (1997): Magnetic resonance imaging-based measurement of hippocampal volume in posttraumatic stress disorder related to childhood physical and sexual abuse—a preliminary report. *Biol Psychiatry* 41:23–32.

Chugani HT, Hovda DA, Villablanca JR, Phelps ME, Xu WF (1991): Metabolic maturation of the brain: A study of local cerebral glucose utilization in the developing cat. *J Cereb Blood Flow Metab* 11:35–47.

Cook MJ, Fish DR, Shorvon SD, Straughan K, Stevens JM (1992): Hippocampal volumetric and morphometric studies in frontal and temporal lobe epilepsy. *Brain* 115:1001–1015.

Davis KL, Buchsbaum MS, Shihabuddin L, Spiegel-Cohen J, Metzger M, Frecska E, et al (1998) Ventricular enlargement in poor-outcome schizophrenia. *Biol Psychiatry* 43:783–793.

Degreef G, Ashtari M, Bogerts B, Bilder RM, Jody DN, Alvir

JM, et al (1992): Volumes of ventricular system subdivisions measured from magnetic resonance images in first-episode schizophrenic patients. *Arch Gen Psychiatry* 49:531–537.

DeLisi LE, Sakuma M, Tew W, Kushner M, Hoff AL, Grimson R (1997): Schizophrenia as a chronic active brain process: A study of progressive brain structural change subsequent to the onset of schizophrenia. *Psychiatry Res: Neuroimaging* 74: 129–140.

DeLisi LE, Stritzke P, Riordan H, Holan V, Boccio A, Kushner M, et al (1992): The timing of brain morphological-changes in schizophrenia and their relationship to clinical outcome. *Biol Psychiatry* 31:241–254.

Diggle PJ, Liang KY, Zeger SL (1994): *Analysis of Longitudinal Data.* Oxford: Oxford University Press.

Dwork AJ (1997): Postmortem studies of the hippocampal formation in schizophrenia. *Schizophr Bull* 23:385–402.

Frazier JA, Giedd JN, Hamburger SD, Albus KE, Kaysen D, Vaituzis AC, et al (1996): Brain anatomic magnetic resonance imaging in childhood onset schizophrenia. *Arch Gen Psychiatry* 53:617–624.

Giedd JN, Castellanos FX, Rajapakse JC, Vaituzis AC, Rapoport JL (1997): Sexual dimorphism of the developing human brain. *Prog Neuropsychopharmacol Biol Psychiatry* 21:1185–1201.

Giedd JN, Kozuch P, Kaysen D, Vaituzis AC, Hamburger SD, Bartko JJ, et al (1995): Reliability of cerebral measures in repeated examinations with magnetic resonance imaging. *Psychiatry Res* 61:113–119.

Giedd JN, Snell JW, Lange N, Rajapakse JC, Kaysen D, Vaituzis AC, et al (1996a): Quantitative magnetic resonance imaging of human brain development: Ages 4–18. *Cereb Cortex* 6:551–560.

Giedd JN, Vaituzis AC, Hamburger SD, Lange N, Rajapakse JC, Kaysen D, et al (1996b): Quantitative MRI of the temporal lobe, amygdala, and hippocampus in normal human development: Ages 4–18 years. *J Comp Neurol* 366:223–230.

Gur RC, Cowell PE, Turetsky BI, Gallacher F, Cannon TD, Bilker W, et al (1998): A follow up magnetic resonance imaging study of schizophrenia. Relationship of neuroanatomic changes to clinical and neurobehavioral measures. *Arch Gen Psychiatry* 55:145–152.

Heckers S, Heinsen H, Heinsen YC, Beckmann (1990): Limbic structures and lateral ventricle in schizophrenia. *Arch Gen Psychiatry* 47:1016–1022.

Huttenlocher PR (1984): Synapse elimination and plasticity in developing human cerebral cortex. *Am J Ment Defic* 88:488–496.

Illowsky BP, Juliano DM, Bigelow LB, Weinberger DR (1988): Stability of CT scan findings in schizophrenia: Results of an 8 year follow-up study. *J Neurol Neurosurg Psychiatry* 51:209–213.

Jacobsen LK, Giedd JN, Castellanos FX, Vaituzis AC, Hamburger SD, Kumra S, et al (1998a): Progressive reduction of temporal lobe structures in childhood-onset schizophrenia. *Am J Psychiatry* 155:678–685.

Jacobsen LK, Rapoport JL (1998b): Research update: Childhood-onset schizophrenia: Implications of clinical and neurobiological research. *J Child Psychol Psychiatry* 39:101–113.

Keshavan MS, Haas GL, Kahn CE, Aguilar E, Dick EL, Schooler NR, et al (1998): Superior temporal gyrus and the course of early schizophrenia: Progressive, static, or reversible? *J Psychiatr Res* 32:161–167.

Kumra S, Jacobsen LK, Lenane M, Karp BI, Frazier JA, Smith AK, et al (1998): Childhood-onset schizophrenia: An open-label study of olanzapine in adolescents. *J Am Acad Child Adolesc Psychiatry* 37:377–385.

Lawrie SM, Abukmeil SS (1998): Brain abnormality in schizophrenia—A systematic and quantitative review of volumetric magnetic resonance imaging studies. *Br J Psychiatry* 172: 110–120.

Lim KO, Harris D, Beal M, Hoff AL, Minn K, Csernansky JG, et al (1996): Gray matter deficits in young onset schizophrenia are independent of age of onset. *Biol Psychiatry* 40:4–13.

Marsh L, Suddath RL, Higgins N, Weinberger DR (1994): Medial temporal lobe structures in schizophrenia: Relationship of size to duration of illness. *Schizophr Res* 11:225–238.

McKenna K, Gordon CT, Lenane M, Kaysen D, Fahey K, Rapoport JL (1994): Looking for childhood-onset schizophrenia: The first 71 cases screened. *J Am Acad Child Adol Psychiatry* 33:636–644.

Nelson MD, Saykin AJ, Flashman LA, Riordan HJ (1998): Hippocampal volume reduction in schizophrenia as assessed by magnetic resonance imaging—A meta-analytic study. *Arch Gen Psychiatry* 55:433–440.

Nolte J (1993): Olfactory and limbic systems. In: Farrell R, editor. *The Human Brain. An Introduction to Its Functional Anatomy,* 3rd ed. St. Louis: Mosby-Year Book, Inc., pp 397–413.

Overall JE, Gorham DE (1961): The brief psychiatric rating scale. *Psychol Rep* 10:799–812.

Rapoport JL, Giedd J, Kumra S, Jacobsen L, Smith A, Lee P, et al (1997): Childhood-onset schizophrenia—Progressive ventricular change during adolescence. *Arch Gen Psychiatry* 54:897–903.

Rasband W (1993): *Image (1.6),* Bethesda, MD: National Institues of Health (Public Domain).

Selemon LD, Goldman-Rakic P (1999): The reduced neuropil hypothesis: A circuit based model of schizophrenia. *Biol Psychiatry* 45:17–25.

Sheline YI (1998): Neuroanatomical changes associated with unipolar major depression. *Neuroscientist* 4:331–334.

Shenton ME, Kikinis R, Jolesz FA, Pollak SD, LeMay M, Wible CG, et al (1992): Abnormalities of the left temporal lobe and thought disorder in schizophrenia. A quantitative magnetic resonance imaging study. *N Engl J Med* 327:604–612.

Snell JW, Merickel MB, Ortega JM, Goble JC, Brookeman JR, Kassell NF (1995): Model-based boundary estimation of complex objects using hierarchical active surface templates. *Pattern Recognition* 28:1599–1609.

Ware JH, Dockery DW, Louis TA, Xu XP, Ferris BG, Speizer FE (1990): Longitudinal and cross-sectional estimates of pulmonary-function decline in never-smoking adults. *Am J Epidemiol* 132:685–700.

Watkins JM, Asarnow RF, Tanguay PE (1988): Symptom development in childhood onset schizophrenia. *J Am Acad Child Adol Psychiatry* 6:865–878.

Woods BT (1998): Is schizophrenia a progressive neurodevelopmental disorder? Toward a unitary pathogenetic mechanism. *Am J Psychiatry* 155:1661–1670.